

Technical Aspects of the Recipient Operation in Hand Transplantation

Kodi K. Azari, M.D.,¹ Joseph E. Imbriglia, M.D.,² Robert J. Goitz, M.D.,²
Jaimie T. Shores, M.D.,³ Marshall L. Balk, M.D.,² Gerald Brandacher, M.D.,⁴
Stephan Schneeberger, M.D.,⁴ Vijay Gorantla, M.D., Ph.D.,²
and W.P. Andrew Lee, M.D.⁴

ABSTRACT

The goal of hand allotransplantation is to achieve graft survival and useful long-term function. To achieve these goals, precise surgical technique is of critical importance. The key surgical steps and sequence of events in hand allotransplantation are similar to major upper extremity replantations, but are modified to accommodate major conceptual differences that exist between the two procedures.

KEYWORDS: Hand transplantation, surgical technique, recipient operation

The ultimate goal of hand allotransplantation is to achieve graft survival and useful long-term function. To achieve these stated goals, selection of the appropriate patient, accurate preoperative planning, and precise surgical technique are of paramount importance.

Allotransplantation is not a suitable treatment for everyone with an upper extremity amputation. This treatment modality should be reserved for motivated consenting adults that are in good general health, psychologically stable, and have failed a trial of prosthetic use. Ideal candidates are those with favorable amputation mechanisms and levels. Certainly, the more distal amputation levels (e.g., wrist and metacarpal hand) are ideal as the nerve anastomosis will be closer to the target end organ and the intrinsic muscles innervate sooner. More proximal amputations, such as the proximal 1/3 of the forearm and above the elbow, remain somewhat controversial at the current time. Furthermore, patients with sharp guillotine-style

amputation mechanisms are preferable to those involving avulsions, crush mechanisms, or burns.

SURGICAL TECHNIQUE

The surgical techniques employed for vascularized composite hand allotransplantation share their roots with replantation surgery.¹ The key steps and sequence of events are similar to major upper extremity replantations, but are modified to accommodate the three major conceptual differences that exist between replantation and allotransplantation, namely, availability of tissues, bone length, and relative tendon tension.

With replantation, there is paucity of tissues, thus the need for bone shortening to alleviate tension on the neurovascular and tendon repairs. However, the relative tension between the flexor and extensor tendons is generally left intact. On the other hand, with allotransplantation, one has adequate tissues and can take exactly

¹Division of Plastic Surgery, Department of Orthopaedic Surgery, David Geffen School of Medicine at UCLA, Los Angeles, California;

²Department of Orthopedic Surgery; ³Division of Plastic Surgery, University of Pittsburgh School of Medicine, Pittsburgh, Pennsylvania;

⁴Department of Plastic and Reconstructive Surgery, Johns Hopkins University School of Medicine, Baltimore, Maryland.

Address for correspondence and reprint requests: Kodi Azari, M.D., F.A.C.S., Associate Professor, Division of Plastic Surgery,

Department of Orthopaedic Surgery, 10945 Le Conte Avenue, Suite 3355, Los Angeles, CA 90095 (e-mail: kazari@mednet.ucla.edu).

J Reconstr Microsurg. Copyright © by Thieme Medical Publishers, Inc., 333 Seventh Avenue, New York, NY 10001, USA. Tel: +1(212) 584-4662.

Received: February 4, 2011. Accepted: March 8, 2011.

DOI: <http://dx.doi.org/10.1055/s-0031-1285820>.

ISSN 0743-684X.

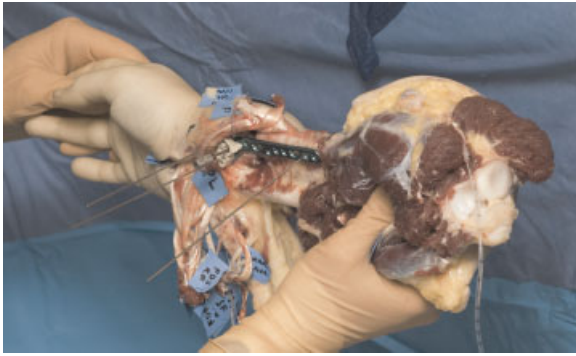


Figure 1 The hand allograft allows the luxury of supplying adequate tissues to reconstruct the recipient's unique requirements.

what is needed to suite the recipient's unique requirements (Fig. 1). However, the relative tension between the flexor and extensor tendons must be reestablished. The third major difference between replantation and hand transplantation is forearm length. Barring major traumatic bone loss, forearm length is generally preserved with replantations (except the small amount taken for bone shortening). With transplantation, however, the appropriate forearm length must be reconstructed to match the contralateral side (Fig. 2).

The operative sequence of hand transplantation varies based on the amount of muscle carried by the graft. Distal transplantations (distal to the distal 1/3 of the radius) carry very little muscle mass, thus theoretically tolerate longer ischemia times. Proximal forearm transplantations, however, include significant muscle bulk so rapid revascularization is necessary as to avoid ischemic injury and prevent subsequent muscle fibrosis.

Hand allotransplantation is done under tourniquet control^{2,3} and general anesthesia with regional

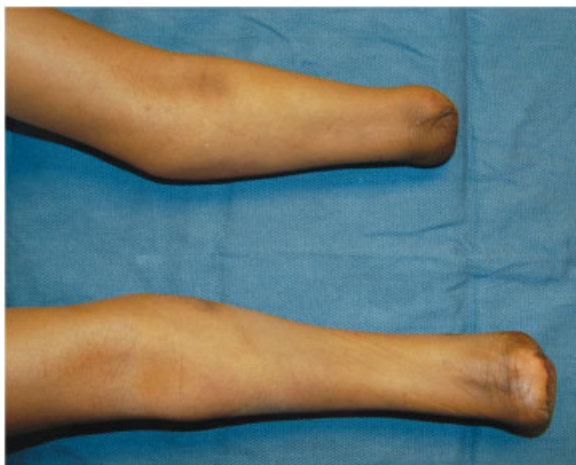


Figure 2 The forearms of a bilateral hand transplantation recipient candidate. One of the goals of allotransplantation is to appropriately reconstruct and match forearm lengths.

anesthetic augmentation for vasodilation and postoperative pain control. The surgical sequence begins with bone preparation and osteosynthesis; revascularization by anastomosis of one main artery and two veins; tendon/muscle repair; definitive vessel repair; nerve repair; followed by skin closure.

This sequence of events is, in particular recommended for proximal (proximal to the mid forearm) transplantations where revascularization is of utmost importance.⁴ However, based on our experience with eight hand/forearm transplantations at the University of Pittsburgh Medical Center, we have modified the operative sequence of events for transplantations distal to the mid-forearm so that revascularization is performed later in the operative sequence. We initially begin with osteosynthesis; however, instead of revascularization, the extensor tendons are next repaired, followed by rapid anastomosis of one to two dorsal veins. Then, the forearm is turned over and nerve repair is accomplished. Both radial and ulnar arteries are next repaired, followed by more veins. This is followed by flexor tendon repair and skin closure.

The above-sequence modification was employed by our team for transplantations distal to the mid-forearm for several reasons. The primary reason is that the repair of the dorsal veins and major nerves is easier under a bloodless field. This is particularly true with the median and ulnar nerves where precise group fascicular repair of the individual motor and sensory branches can be performed in hopes of better return of future function. After reperfusion, we have found that group fascicular cannot be performed due to severe nerve edema and blood staining. We have been able to make these modifications because the same surgical team does the operation each time, thus providing comfort and familiarity with the surgical sequence, and an invaluable advantage of being able to rapidly move through the operation. Additionally, with more distal amputations, longer ischemia times are felt to be more tolerable.

TEAM COORDINATION

The hand allotransplantation operation mandates a multifaceted surgical approach to try and keep ischemia times as short as possible. At least two operative teams for unilateral and four teams for bilateral operations are required that work simultaneously (Fig. 3) and in concert on the donor and recipient.⁵⁻⁷ We have found that it is ideal to have the recipient and "back table" donor teams in the same operating room so that perfect coordination of transplant timing and tissue requirements can be communicated in real time. If large enough operating rooms are not available, then the donor and recipient teams should, at the very least, be located in adjacent operative theaters.

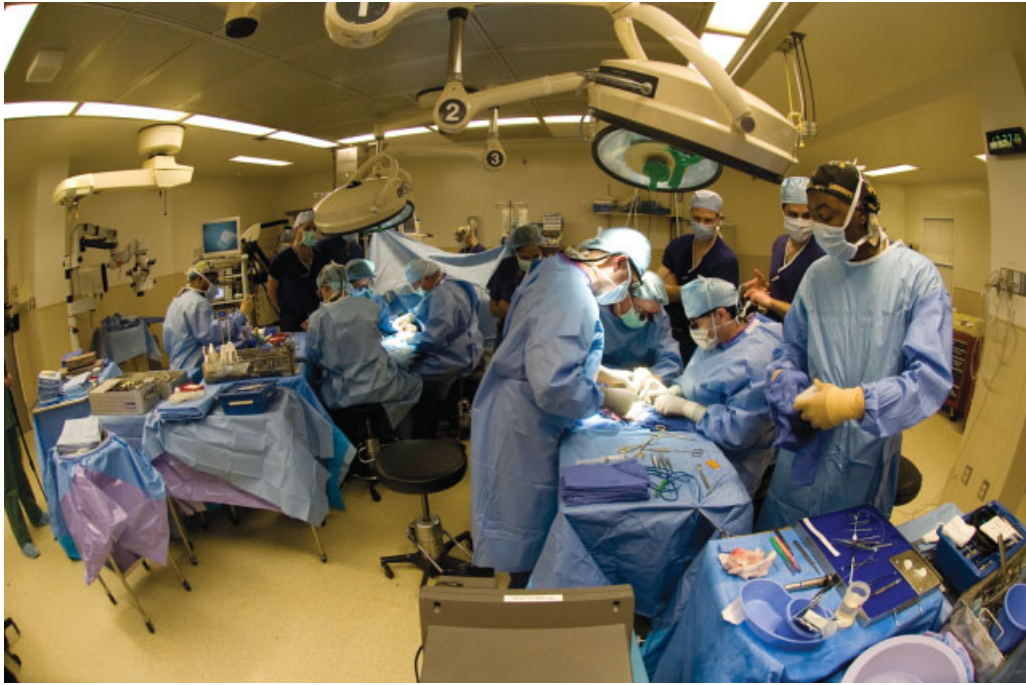

Figure 3 The operating room set-up for a unilateral hand transplant operation. At least two operative teams are required that work simultaneously on the recipient and on the donor limb on a “back table.”

TIMING

The timing of the hand transplant operation depends on the condition and geographic location of the donor limb. If the procurement team deems that the donor limb is in excellent condition, then the recipient can be brought to the operating room for stump preparation prior to the donor limb arrival. Obviously, the timing must be coordinated based on geographic location and travel times. If, however, there is any concern about the condition of the donor limb such as vascular injury or thrombosis from arterial lines or intravenous catheters, then it is prudent to not proceed with the recipient stump dissection first. In this instance, the donor limb should be recovered in the usual fashion, brought back, and carefully examined on the back table prior to recipient dissection. It could be that on table angiogram or donor limb dissection is warranted prior to making the decision to proceed with transplantation.

SKIN INCISIONS

The design of the skin incisions is of paramount importance. The goal of the incisions is the removal of unhealthy and scarred tissue and closure in a non-constrictive manner (Fig. 4). Because extensive dissection may be required, we have found that the four-flap interposing incision provides optimal exposure of structures and creates a zigzag skin flap closure that does not result in a circumferential scar contracture. The interposing four-flap design is created by the placement of mid-lateral incisions on the recipient

stump and dorsal and volar midline incisions on the donor limb. The donor limb volar midline incision can easily be extended to decompress the carpal canal (Fig. 5A, B).

DISSECTION AND IDENTIFICATION OF STRUCTURES

Dissection of donor and recipient limbs, as mentioned earlier, should be performed simultaneously and ideally in the same operating room. The preparation of the recipient stump is often difficult and must be performed carefully as the structures may be encased in scar, tenuous, and atrophied. This is particularly the case

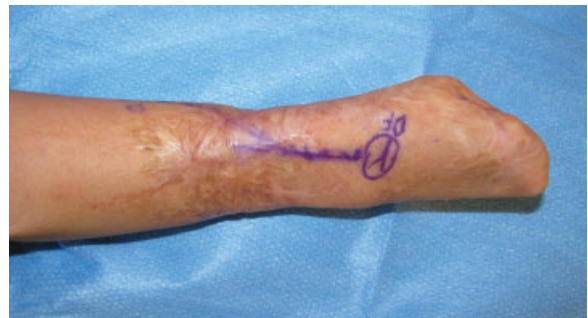

Figure 4 Preoperative appearance of a unilateral hand transplant recipient’s “metacarpal hand” that was the result of meningococcal sepsis. Note the severely scarred tissues that should be replaced with healthy donor tissues if feasible. The skin marking is the course of a preoperatively mapped dorsal vein.

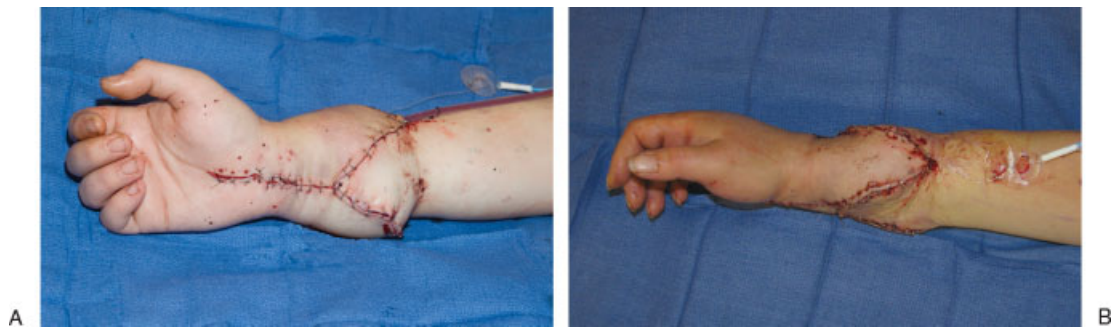


Figure 5 Interposing four-flap design for zigzag incision closure. The donor limb receives midline volar and dorsal incisions and the recipient limb receives mid-lateral incisions. (A) The volar incision is extended distally to decompress the carpal canal. (B) Lateral view

with amputations resulting from explosive injuries, burns, and meningococcal sepsis (Fig. 4). Dissection of the recipient stump should begin in the subcutaneous plane with careful attention to the preservation of the superficial veins that are often diminutive (Fig. 6A, B). We have found that vein mapping of the recipient just prior to transplantation in the preoperative holding area using a portable ultrasound unit aids in the intraoperative identification of these formidably small veins (Fig. 4).

Dissection of the donor limb begins proximally and ends distally from the subcutaneous tissues to the bone. This dissection can be performed rather rapidly and the structures are left long as the excess tissues can easily be discarded later in the operation. Leaving the structures long is particularly important for the skin flaps as the tendon repairs tend to add significant bulk and it is hard to judge the exact amount of skin needed (Fig. 7). Furthermore, the long skin flaps can be an excellent source for full-thickness skin grafts in the event that there is too much tension of the skin

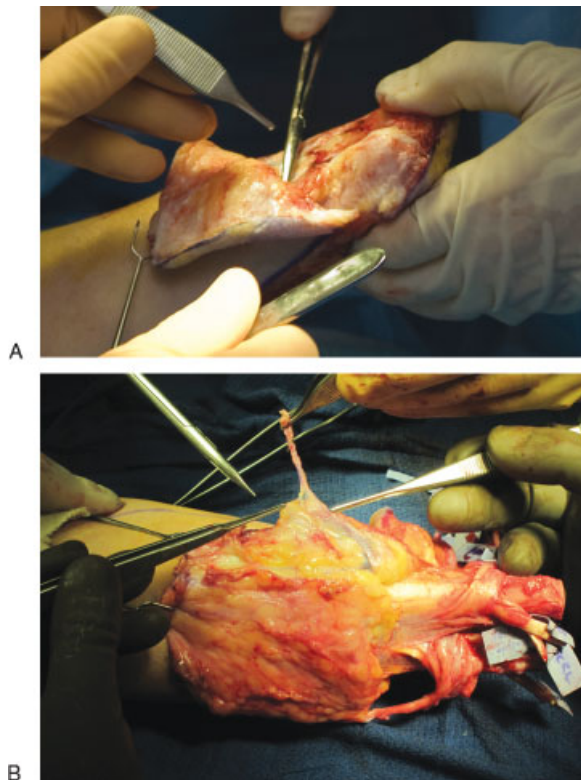


Figure 6 Dissection of the recipient stump. (A) Dissection is made in the subcutaneous plane superficial to the fascia. (B) Careful attention must be given to the preservation of the delicate superficial veins that are often diminutive in size and caliber.

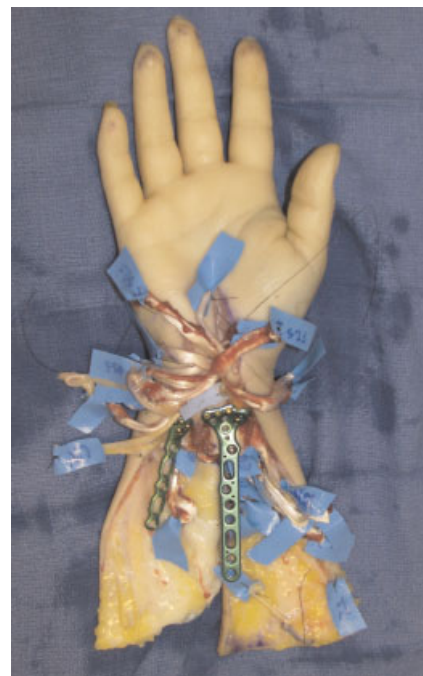


Figure 7 Structures are left along with the donor limb and what is not needed is discarded later in the operation. This is most important for the skin flaps as bulky tendon repairs and postrevascularization edema will make soft tissues coverage requirements difficult to initially estimate. Note that a long distal radius and ulna plate is used for osseous fixation in this distal transplant.

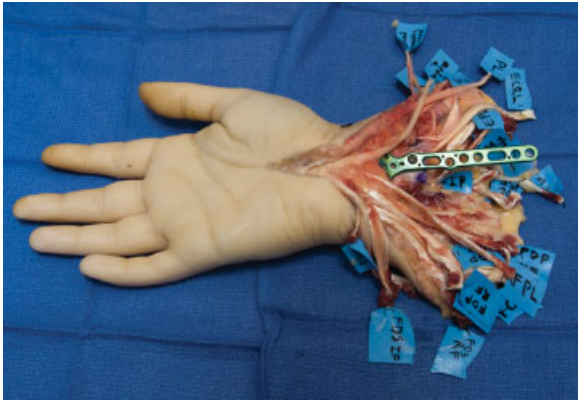


Figure 8 Each donor and recipient structure should be dissected and tagged for easy identification. Tags can be simply made by cutting a rectangular piece of esmarch bandage marked with indelible ink markers and secured with 2–0 silk sutures.

closure at the conclusion of the operation. Particular attention should be paid to the preservation of the distal radial and ulnar artery perforators to ensure skin flap viability.

Once each donor and recipient limb structure is dissected, it must be identified and individually tagged (Fig. 8). The importance of identification tagging of each structure cannot be overemphasized. Hand transplantation is a long procedure that involves the repair of many structures. Once the graft is revascularized, edema and blood staining will make the identification of structures into a daunting task for the tired surgical team and add significant and unnecessary complexity to the oper-

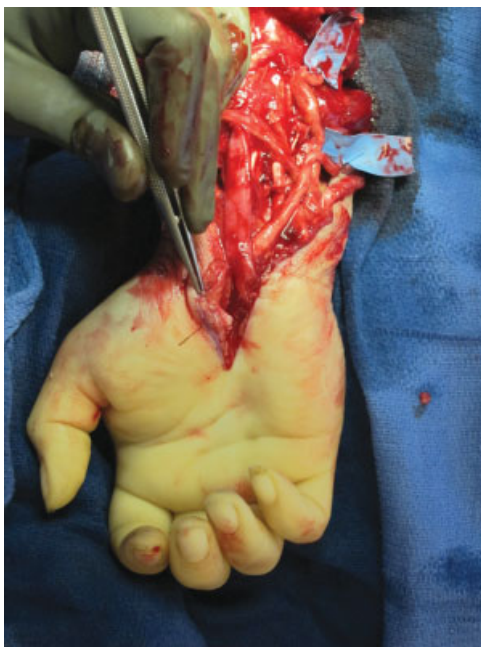

Figure 9 The image depicts the edema and blood staining that occurs after revascularization and underscores the need for secure structure identification tags.

ation if appropriate tagging has not been performed (Fig. 9).

In our routine practice we tag each structure individually with a rectangular piece of esmarch bandage marked with indelible ink markers and secured with 2–0 silk sutures (Fig. 8). The elastic esmarch bandage does not tear easily, the knots of silk sutures do not unravel, and indelible markers do not smear when placed in contact with blood.

BONE FIXATION

The goal of osteosynthesis is to allow early bone union and to reconstruct the forearm length and alignment. The distal radioulnar joint must be congruous and there should be no rotational deformities. We have found that the 3.5-mm locking compression plates (LCPs) are ideal for proximal and mid-forearm transplantations as they provide compression and a rigid construct⁸ (Fig. 10). To promote osseous union, care must be employed to avoid aggressive periosteal stripping.

Distal forearm transplants, however, pose a particular dilemma for osseous fixation in that the 3.5-mm LCP cannot be contoured to the distal aspect of the radius. In these distal transplantations, volar locking distal radius and ulna plates can be utilized (Fig. 7). In our practice, we provisionally plate the donor radius and ulna, then remove the plate and perform our osteotomies. The plates are next reapplied and secured in compression mode to the donor radius and ulna.

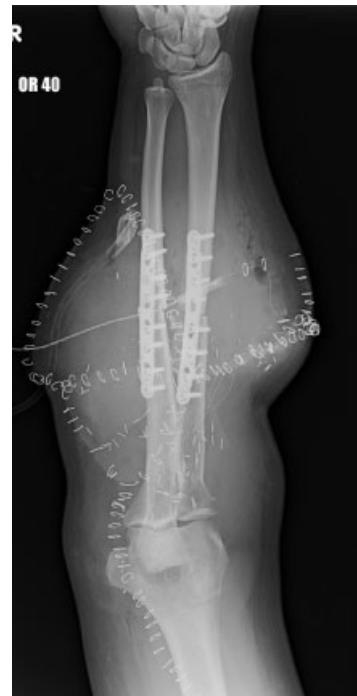

Figure 10 Radiograph depicting a mid-forearm transplantation's radius and ulna rigid osseous fixation using 3.5-mm Locking Compression Plates.

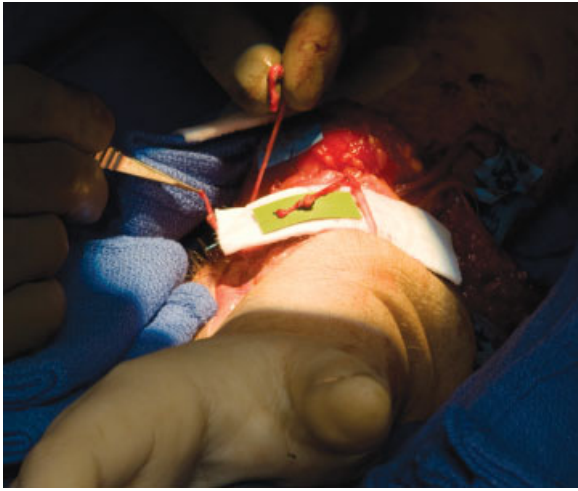

Figure 11 Image depicting the anastomosis of at least four dorsal veins.

VESSEL REPAIR

As mentioned above, in most cases, vascular anastomosis is performed following bone fixation to reestablish flow. Initially, either the radial or ulnar artery is anastomosed in an end-to-end fashion along with one to two veins. We prefer to anastomose the veins first as it is easier to perform in a bloodless field. However, if the veins cannot be easily located, arterial repair is performed first, which will dilate the veins and allow identification. Early revascularization in this rapid manner allows for the tendon repairs to be done without worries about ischemia time. This is, however, at the expense of precise group fascicular nerve repairs being performed in an edema free and bloodless field.

Later, once the tendon and nerve structures are repaired, definitive vascular repair is performed by repairing the other artery and more veins (Fig. 11). It is advisable to anastomose at least four veins from both the superficial and deep systems. Arterial repairs should be

performed in an end-to-end manner, distal to the mid-forearm. In more proximal transplants, the arterial anastomosis should be end to side as to avoid disruption of the proximal muscle belly nutrient branches to avoid potential long-term ischemic contracture and fibrosis.

It is important to note that the operation is done while keeping the graft cool using ice slush for optimal preservation. Once initial revascularization is complete, the ice is removed and the graft warmed with sterile saline irrigation to decrease vasospasm.

MUSCLE/TENDON REPAIR

The technique for repair of muscle/tendons largely depends on the transplantation levels. For muscle repairs proximal to the myotendinous junction, individual muscle units may not be identifiable, and so, individual tendon repairs not possible. In these instances, the only remaining choice becomes epimysium and perimysium repairs. More distally, however, stronger repairs are performed so that early active range of motion can be safely initiated. Our method of choice has been the Pulvertaft weave technique (Fig. 12). It is granted that this method adds bulk and takes longer to perform than some of the end-to-end techniques, such as the Tsuge method.⁹ However, we have found that the trade-off is worth the excellent tendon repair strength and the ability to initiate active range of motion in the very early post-operative period.

Regardless of which muscle tendon repair method is chosen, the ultimate goal is to reestablish the relative tension between the flexor and extensor tendons. It is this author's opinion that this is one of the more difficult challenges of the hand transplant operation. Judgment errors in reestablishing the critical flexor and extensor tendons balance will most certainly lead to postoperative functional limitations that will be very difficult to correct.

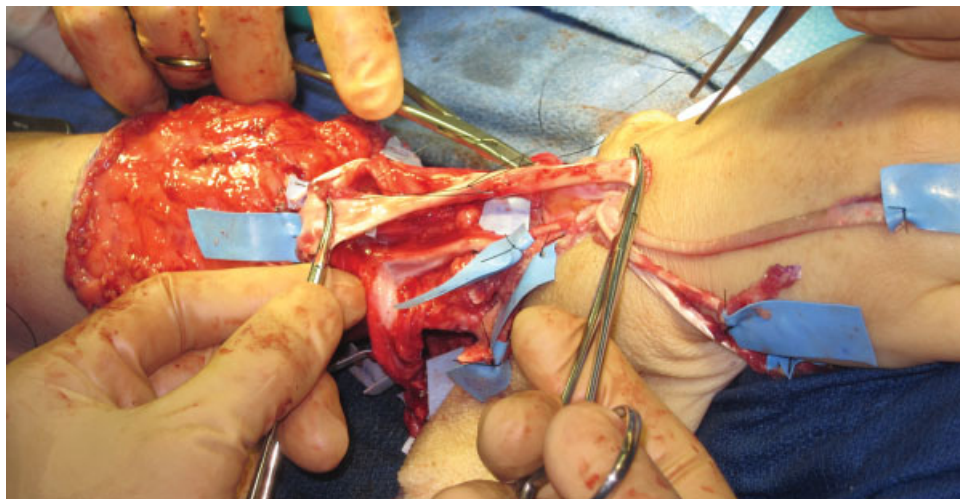


Figure 12 Image depicting the tension adjustment of a Pulvertaft weave for extensor tendon repair.

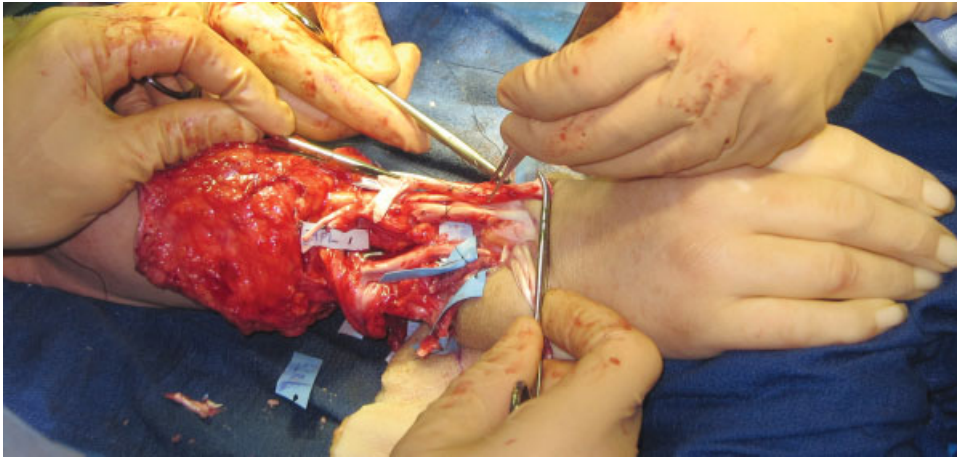


Figure 13 To reestablish the balance between the extensor and flexor tendons, we first begin with the extensor tendons. This image depicts the repair of the wrist extensors, which will be followed by the digit and thumb extensor repairs.

To set the balance, we first begin with the extensor tendons. The wrist extensors are initially repaired followed by the digit and thumb extensors (Fig. 13). The Pulvertaft weave tension is ideally set so that the digits fully extend when the wrist is flexed 20 to 30 degrees. Then the forearm is supinated and the flexor tendons are repaired to a tension that restores the natural resting digital cascade.

NERVE REPAIR

Nerve repair should be performed with the utmost care and precision under the operative microscope. All major forearm/hand nerves: median, ulnar, radial (radial sensory or posterior interosseous nerve) should be repaired. Additionally, depending on the transplantation level, the

palmar cutaneous branch of the median nerve and dorsal ulnar sensory nerve can be repaired.

The repair technique depends on the level of transplantation. Distal amputations such as metacarpal hands or at the radiocarpal level afford the luxury of precise ulnar and median nerve motor and sensory branch dissection and group fascicular anastomosis⁸ (Fig. 14). Proximal transplantations with mixed nerve topography can be repaired based on surgeon's preference by epineurial suture or nerve conduit.

Because of postoperative edema, we routinely perform prophylactic carpal tunnel releases in our hand transplants. We have not had an instance of flexor tendon bowstringing in eight transplanted hands; each with carpal tunnel releases.

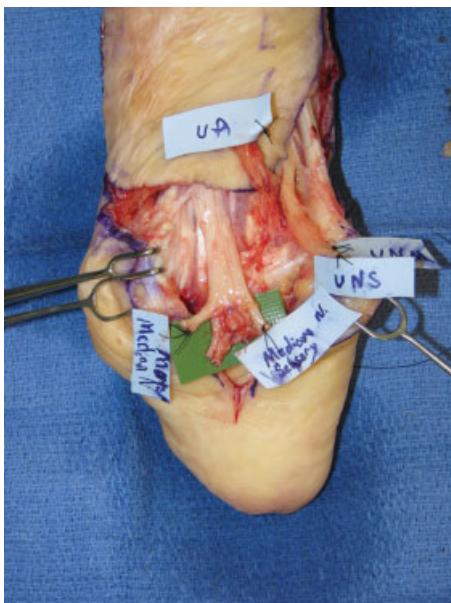

Figure 14 In this "metacarpal hand" recipient, the ulnar and median nerve motor and sensory branches were precisely identified and group fascicular anastomosis performed.

SKIN CLOSURE AND DRESSINGS

Following the repair of structures and prior to skin closure, meticulous hemostasis must be achieved. The

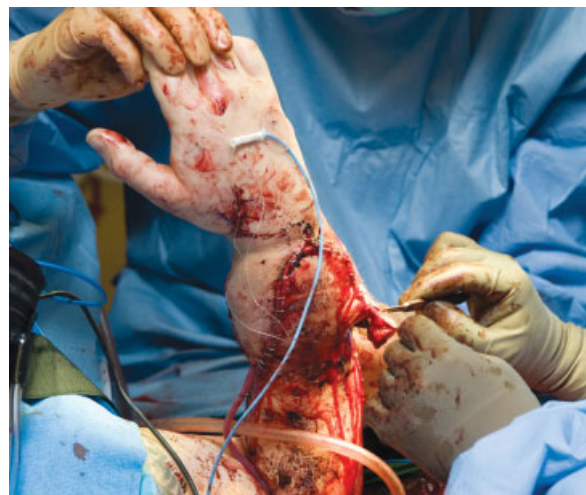

Figure 15 Image depicting the trimming and inset of the skin flaps at the conclusion of the operation.

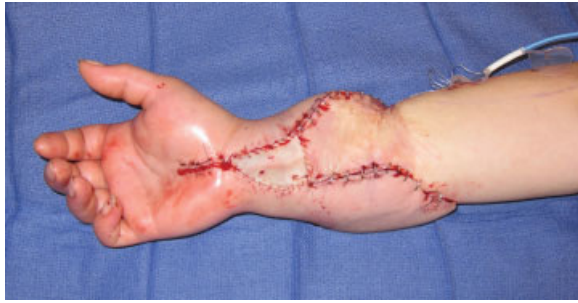

Figure 16 Tight skin closure should be avoided as to not compromise vascularity. In this case a full-thickness skin graft harvested from the donor skin flaps was used to alleviate closure tension.

skin flaps are trimmed and loosely inset over closed suction drains (Fig. 15). The final appearance is four interdigitating flaps that close in a zigzag manner. More often than not, we have found that there is paucity of forearm skin to be able to loosely cover all structures. For obvious reasons, tight closures must be avoided and so full-thickness grafts from the trimmed donor skin are used to alleviate tension (Fig. 16).

At the conclusion of the procedure, dressings that consist of sheets of petroleum gauze, 4 × 4 sponges and a nonconstricting plaster splint are applied.

Flap monitoring is achieved by a dual technique of an implantable Doppler around one of the vein anastomoses and two pulse oximeters. One pulse oximeter is placed on one of the transplanted hand digits and another on the contralateral (nontransplanted) hand or toe (bilateral hand transplants). This double-pulse oximeter technique allows for easy postoperative monitoring by comparing the arterial waveforms and oxygen saturations between the transplanted hand and the non-transplant control.¹⁰

CONCLUSION

In summary, hand allotransplantation requires careful planning and meticulous execution to maximize chan-

ces for surgical success. While most techniques are adapted from traditional replantation surgery, some modifications have been found to be very helpful depending on transplant level and key differences in tissue availability, limb length, and flexor and extensor tendon balance.

REFERENCES

1. Kleinert HE, Jablon M, Tsai TM. An overview of replantation and results of 347 replants in 245 patients. *J Trauma* 1980;20(5):390-398
2. Dubernard JM, Owen E, Herzberg G, et al. Human hand allograft: report on first 6 months. *Lancet* 1999;353(9161):1315-1320
3. Jones JW, Gruber SA, Barker JH, Breidenbach WC. Louisville Hand Transplant Team. Successful hand transplantation. One-year follow-up. *N Engl J Med* 2000;343(7):468-473
4. Schneeberger S, Ninkovic M, Gabl M, et al. First forearm transplantation: outcome at 3 years. *Am J Transplant* 2007;7(7):1753-1762
5. Margreiter R, Brandacher G, Ninkovic M, Steurer W, Kreczy A, Schneeberger S. A double-hand transplant can be worth the effort! *Transplantation* 2002;74(1):85-90
6. Piza-Katzer H, Ninkovic M, Pechlaner S, Gabl M, Ninkovic M, Hussl H. Double hand transplantation: functional outcome after 18 months. *J Hand Surg [Br]* 2002;27(4):385-390
7. Schneeberger S, Ninkovic M, Margreiter R. Hand transplantation: the Innsbruck experience. In: Hewitt CW, Lee WPA eds. *Transplantation of Composite Tissue Allografts*. New York: Springer; 2008:234-250
8. Cavadas PC, Landin L, Ibañez J. Bilateral hand transplantation: result at 20 months. *J Hand Surg Eur Vol* 2009;34(4):434-443
9. Labana N, Messer T, Lautenschlager E, Nagda S, Nagle D. A biomechanical analysis of the modified Tsuge suture technique for repair of flexor tendon lacerations. *J Hand Surg [Br]* 2001;26(4):297-300
10. Chang J, Jones N. Twelve simple maneuvers to optimize digital replantation and revascularization. *Tech Hand Up Extrem Surg* 2004;8(3):161-166